

We save the limbs
that others can't.



The “Second Look”

Kevin Herman, MD

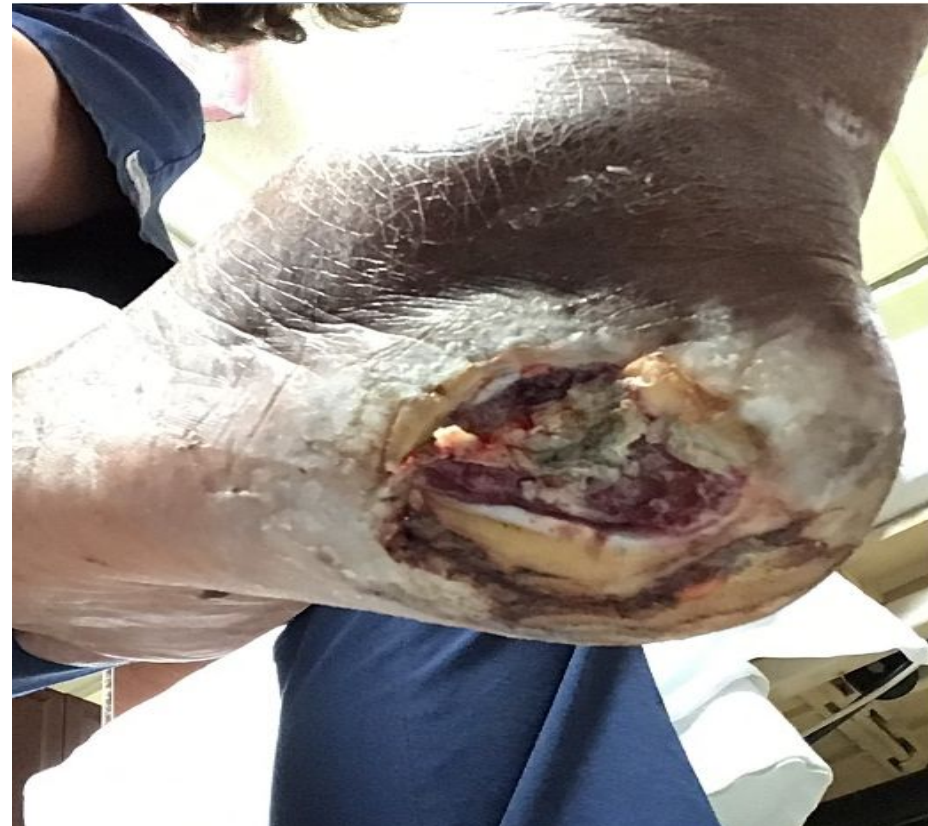

Patient History and Consultation

- 95 year-old female with recent onset of painful left heel ulcer. Non ambulatory. AAOx3. Conversant. Wheelchair dependent, able to transfer.

- PMHx:

DVT	Gastritis
PAD	Dysphagia
CHF	Arthritis
Afib	Weakness
HTN	





Patient Plan and Treatment

- **PLAN**

- Blood Work
- Arterial Imaging (at facility)
- Family Discussion
- Arterial Imaging Same Day for Planning
- Angiogram

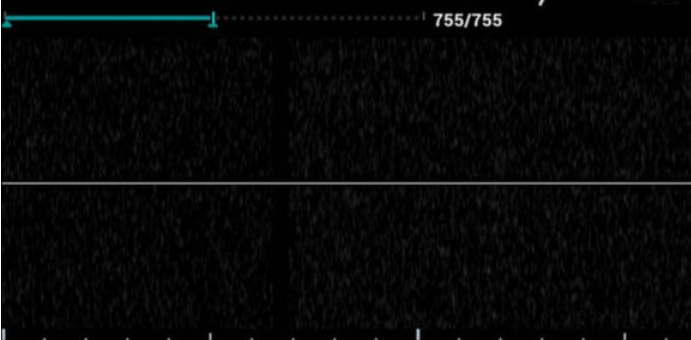
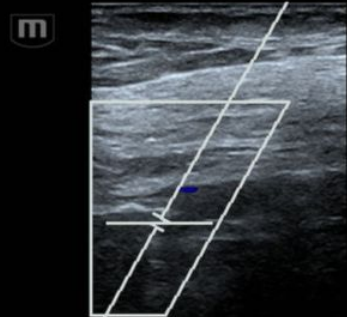
- **TREATMENT**

- IV Abx – Meropenem, broad spectrum antibiotic
- Anti-plt
- Cont. current medical mgmt.

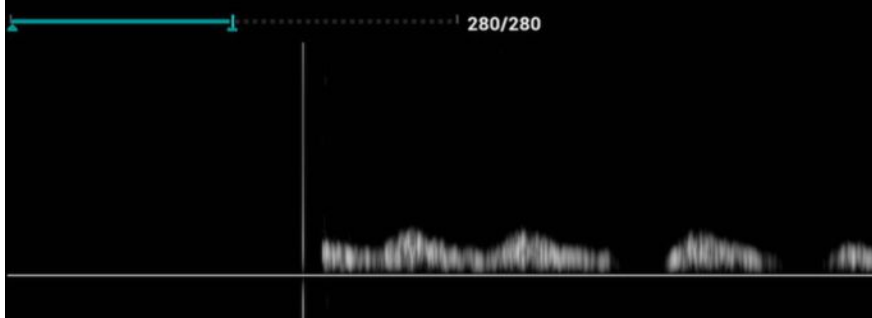
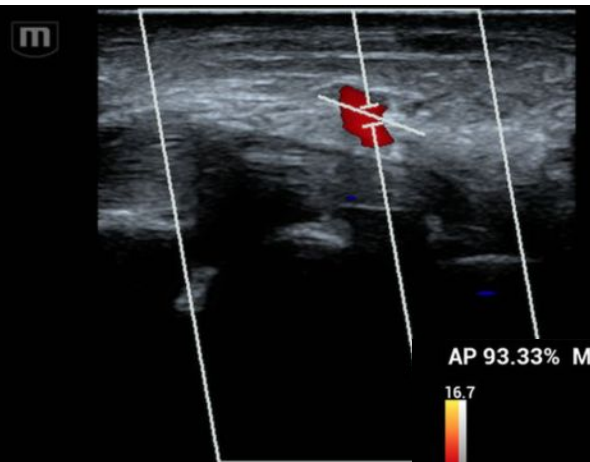
Same Day Arterial Imaging

AP 93.33% MI 0.34 TIS 1.1

LT Pop A



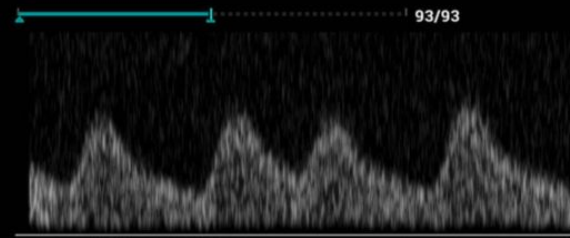
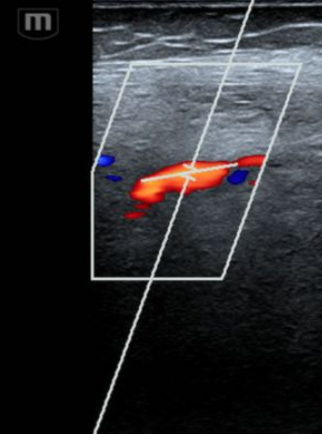
LT Tp-Trunk CPA



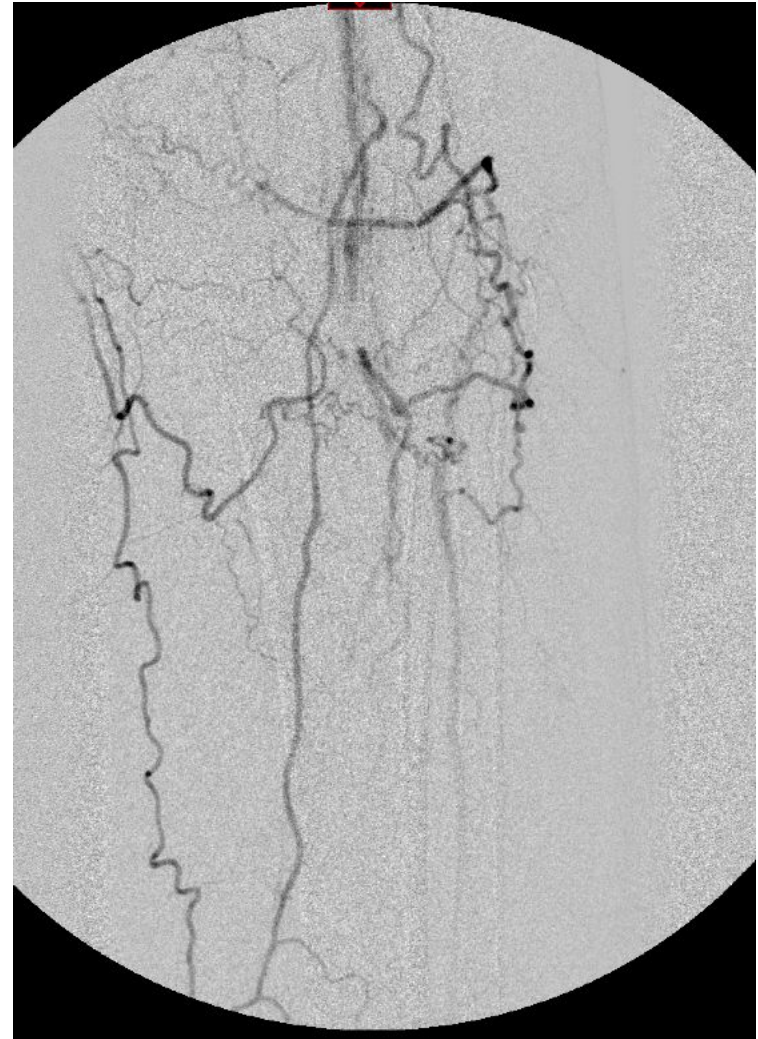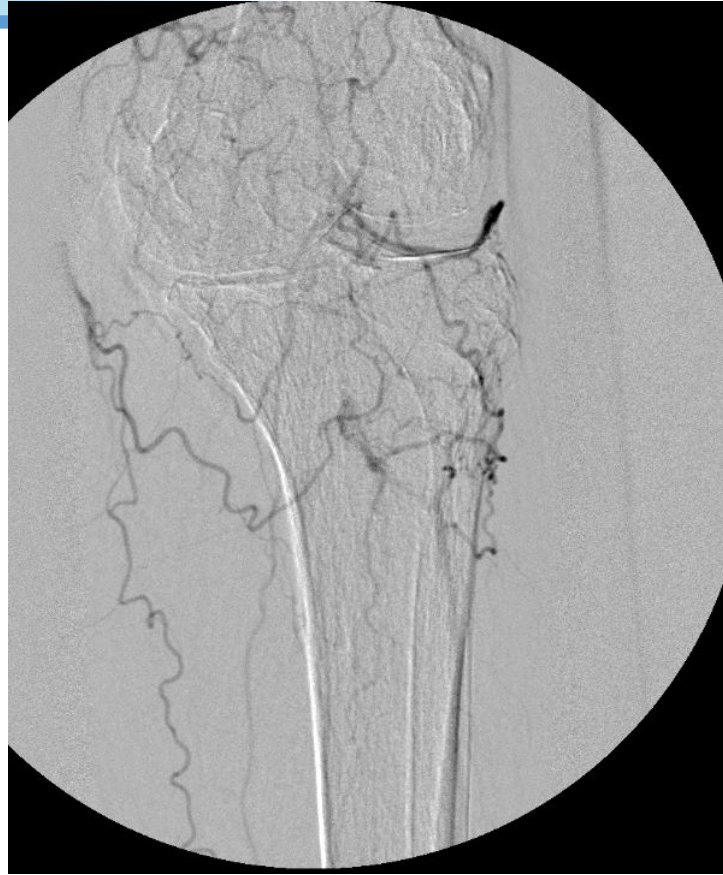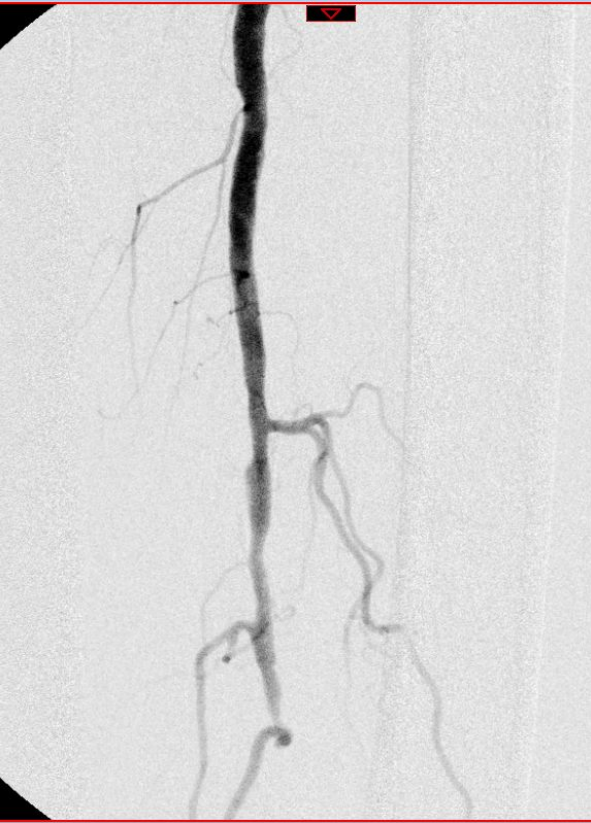AP 93.33% MI 0.60 TIS 0.4

LT

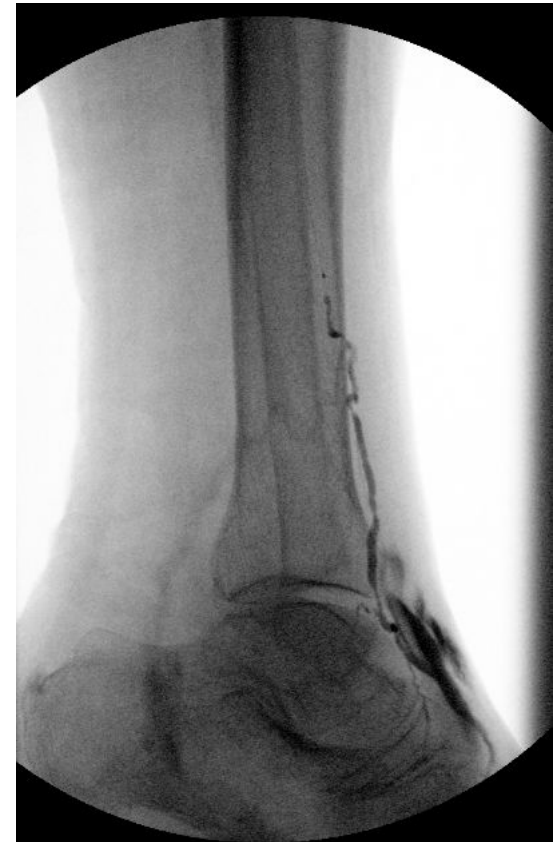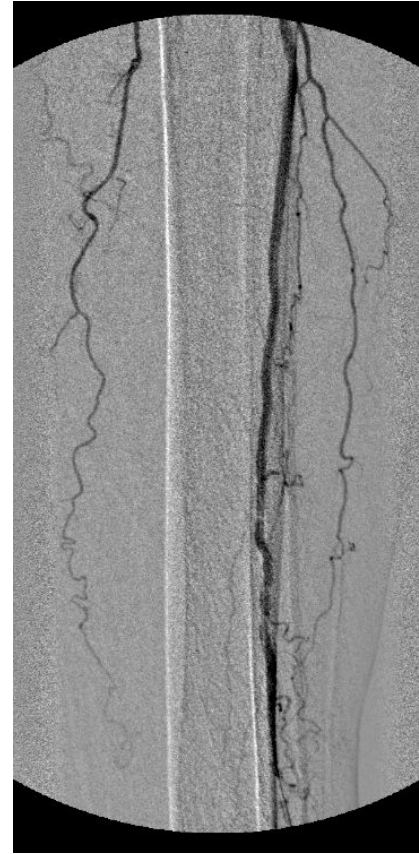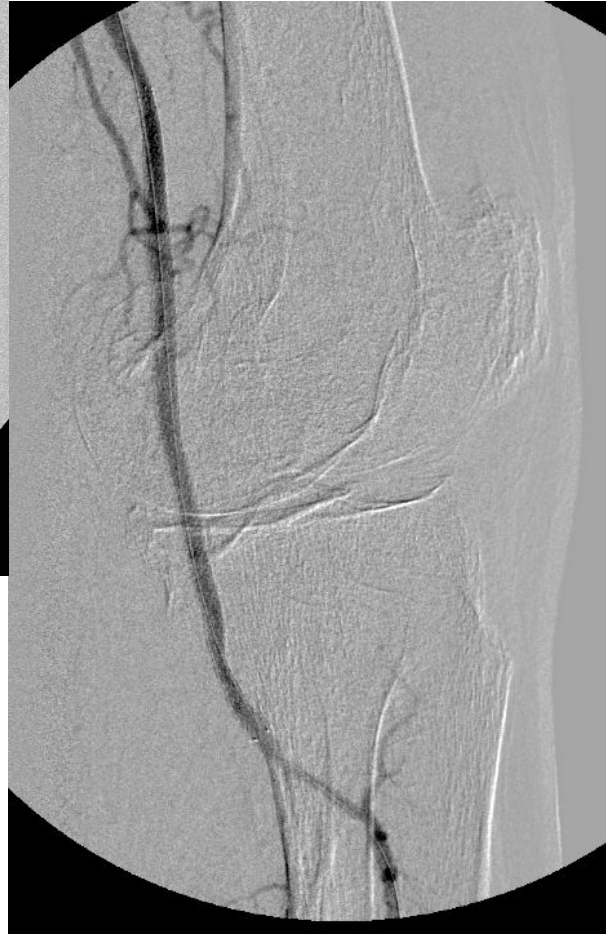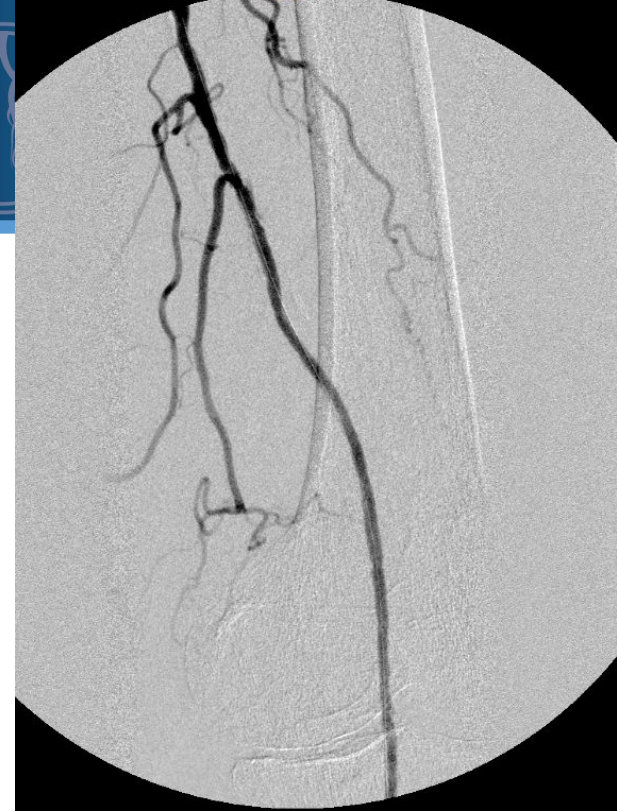Ant Tibial A Prox



Angiogram 5/5/22

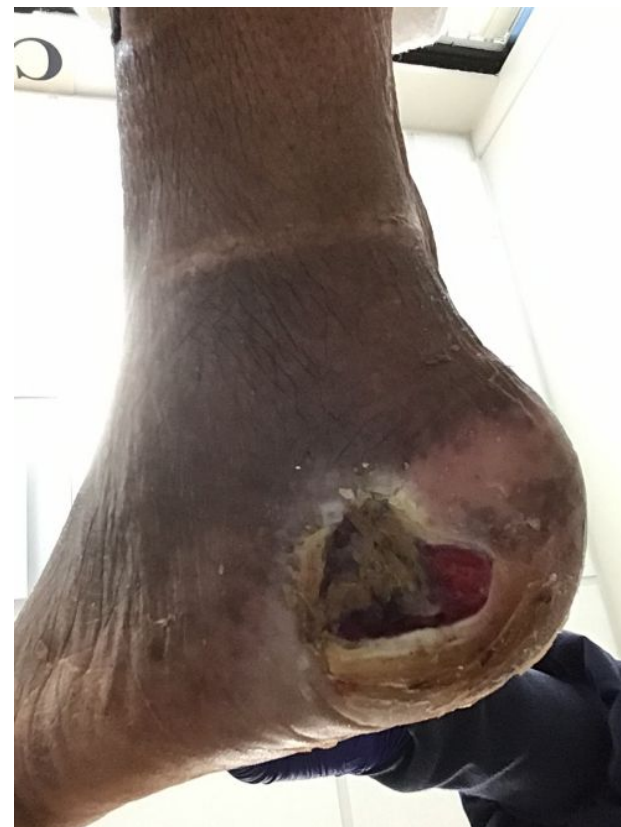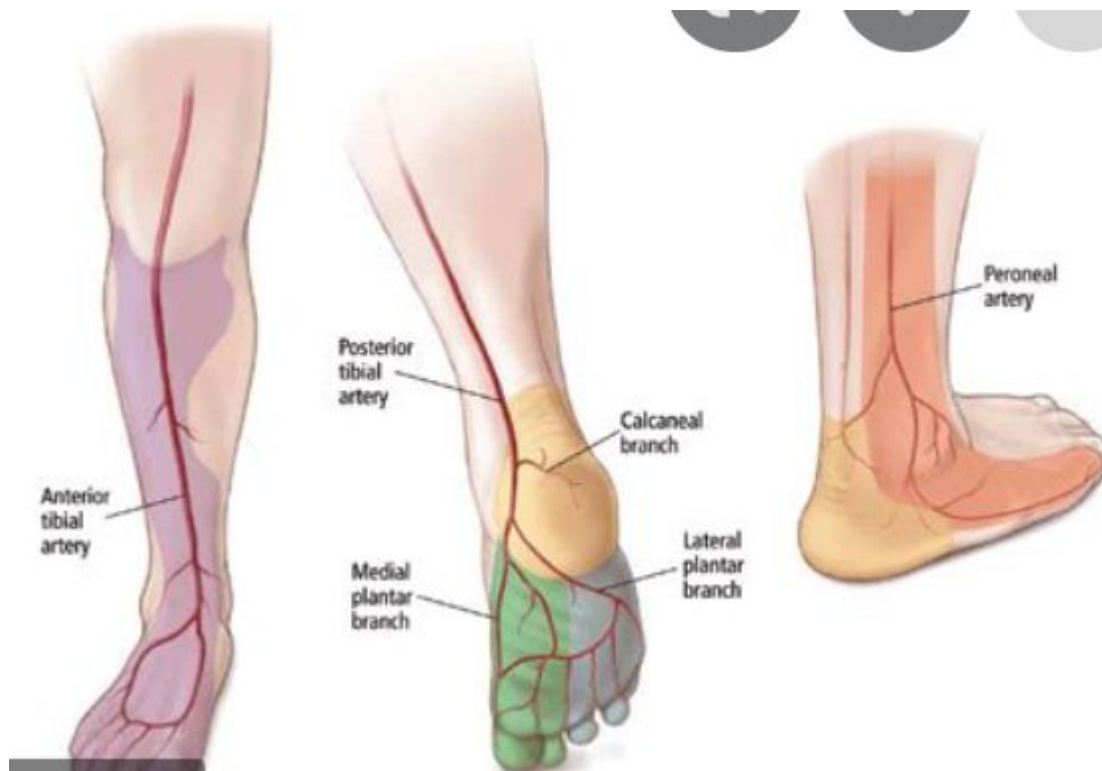


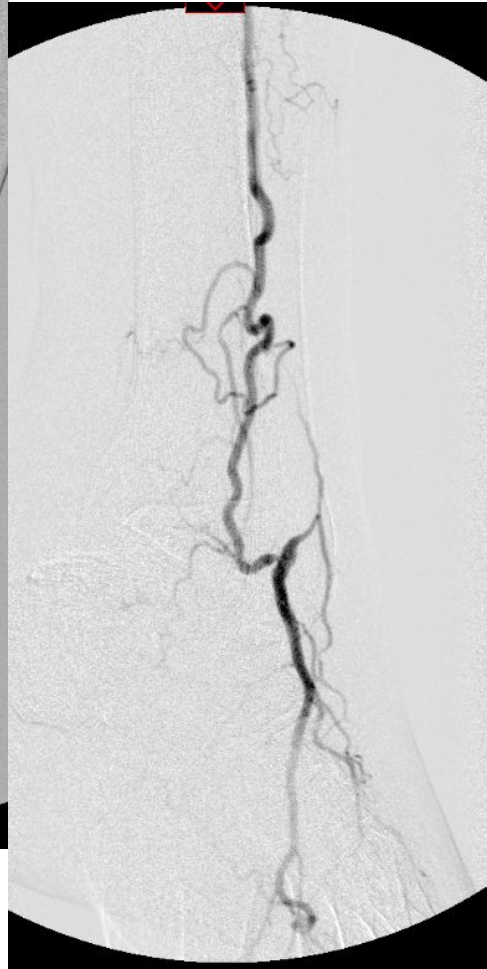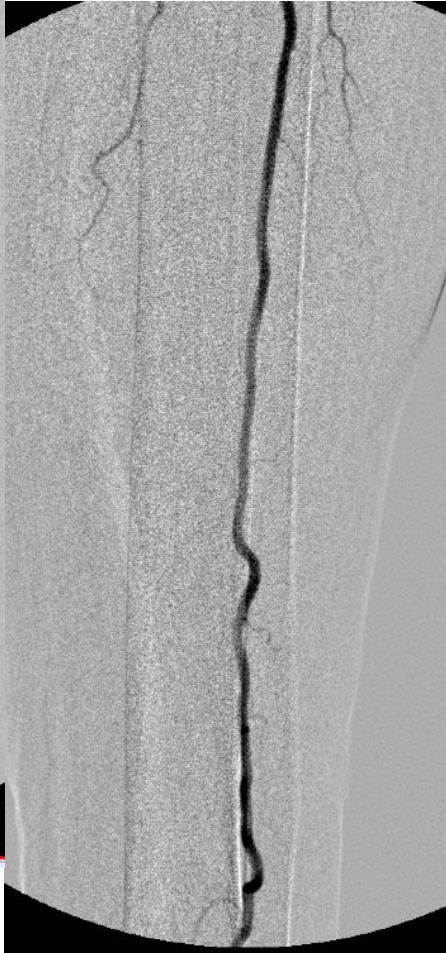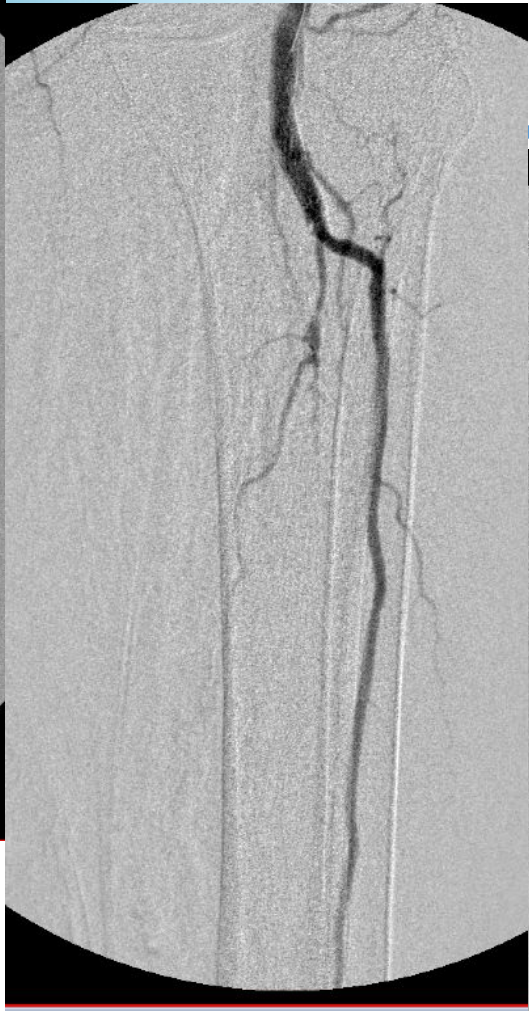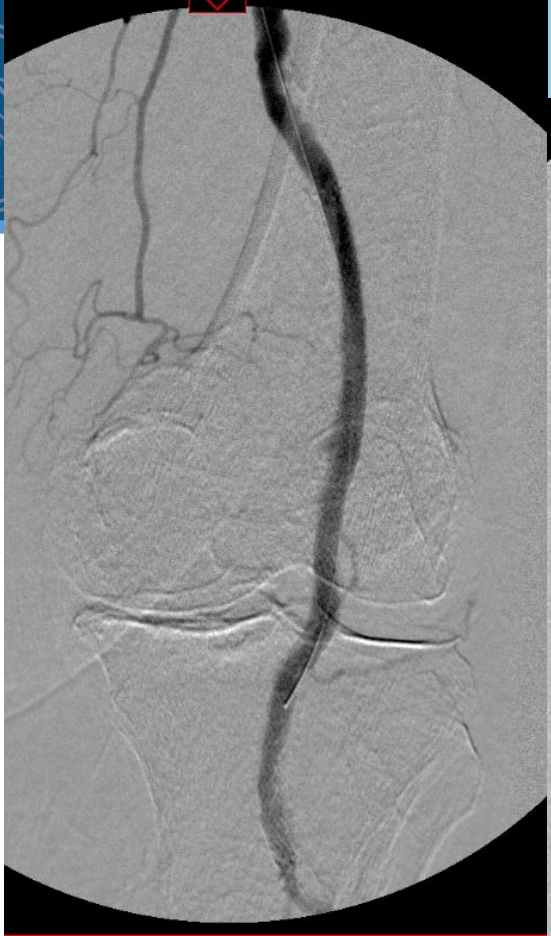Angiogram 5/5/22



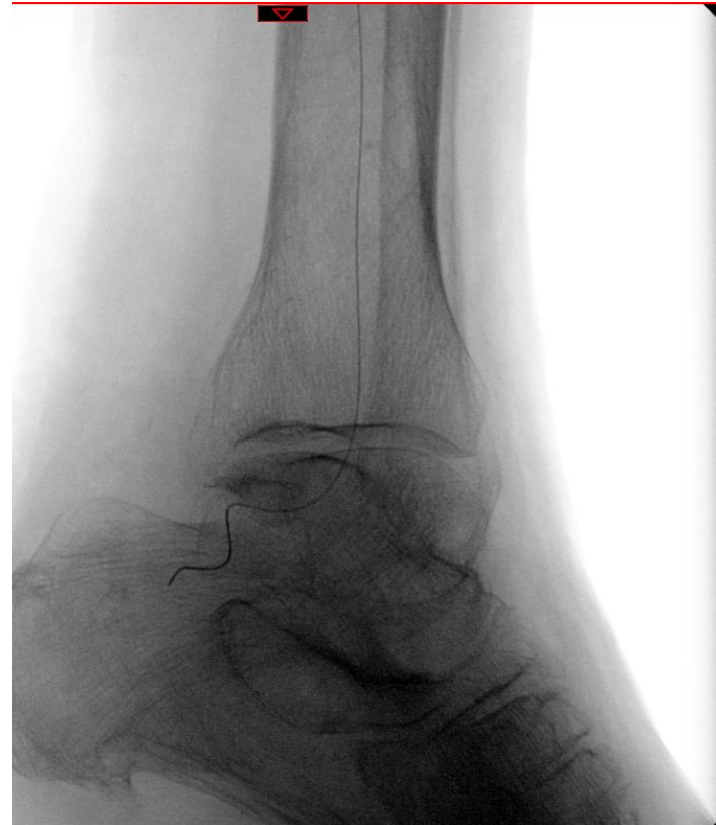
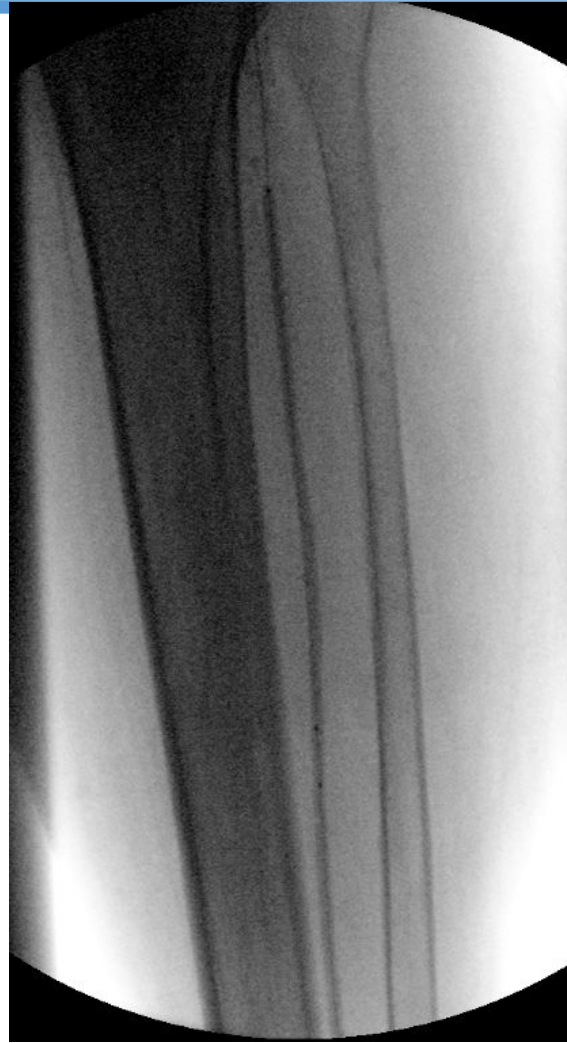
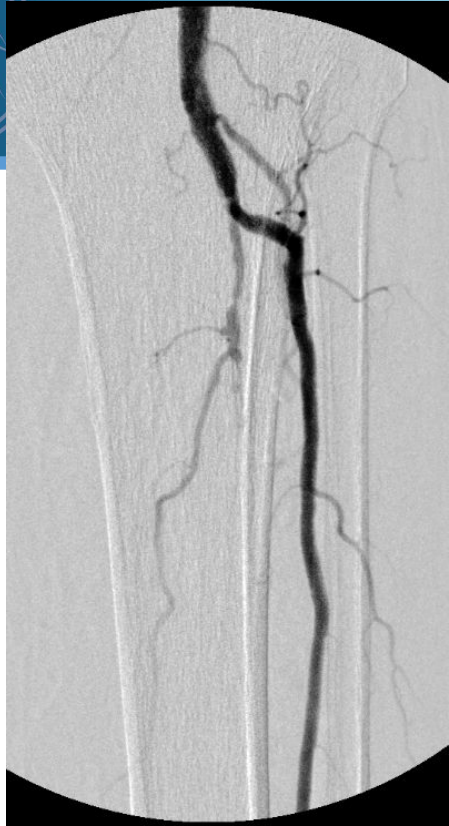Rationale for Second Look



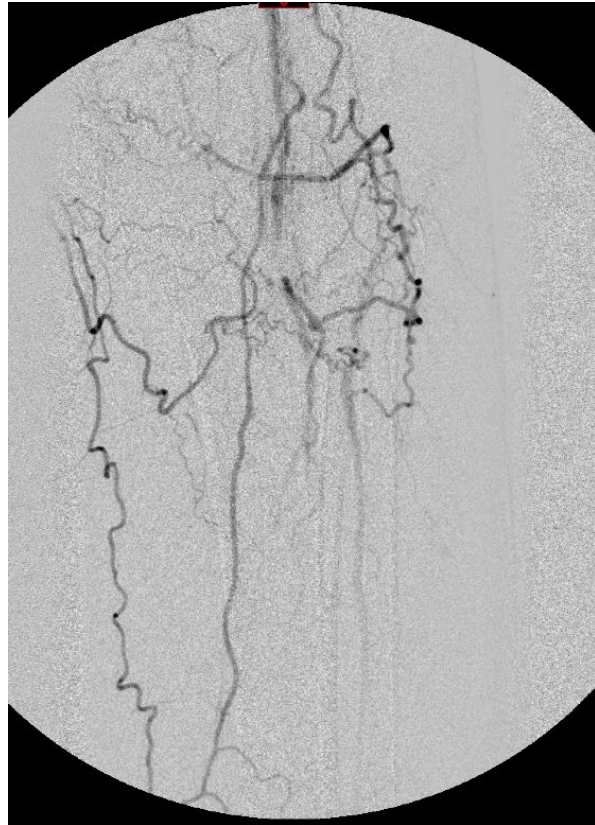

Second Look Intervention

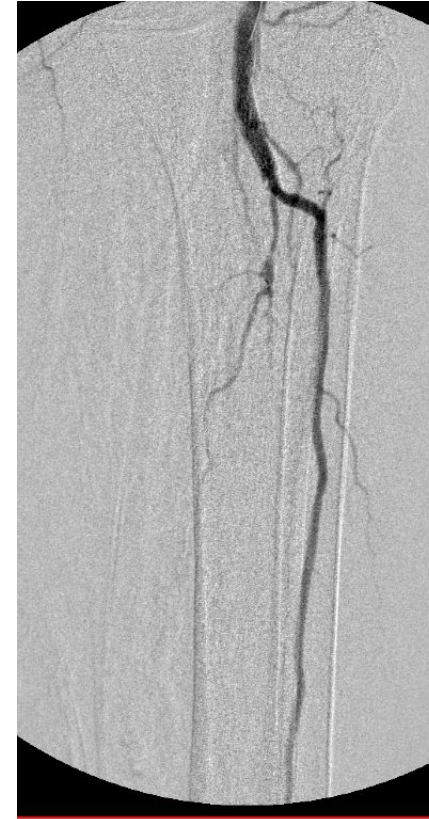



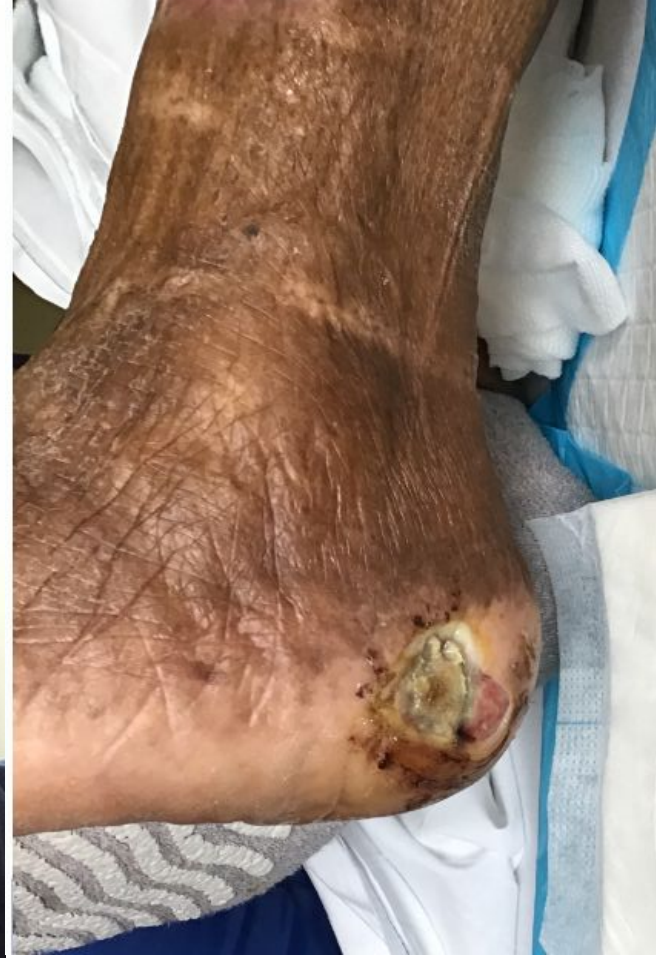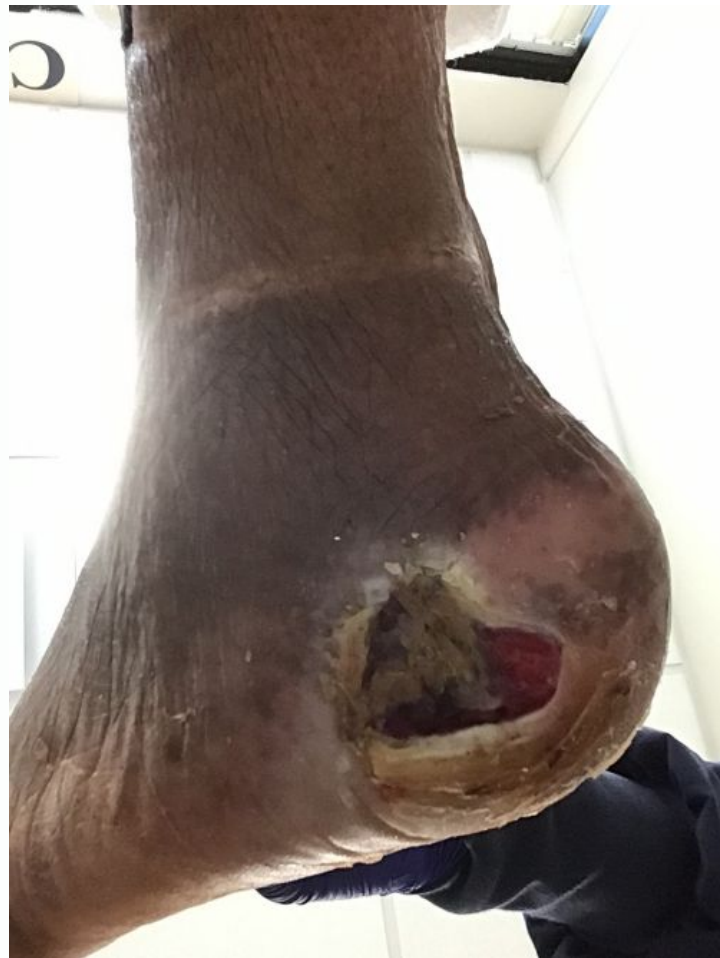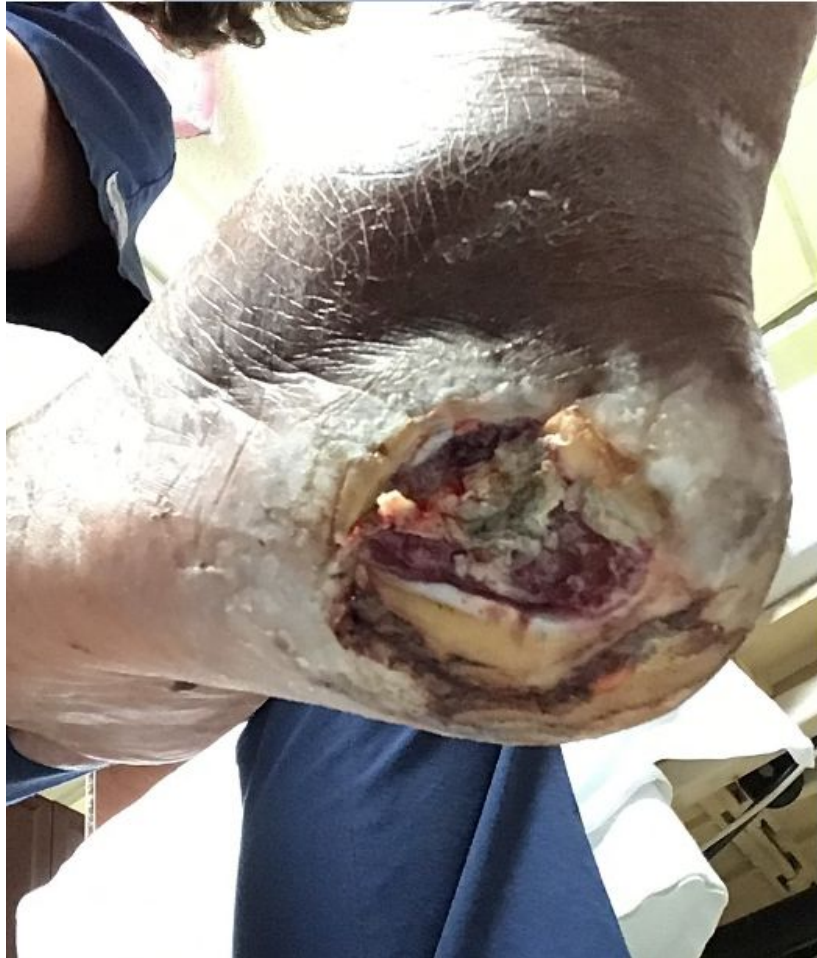Initial Angio



Angio @
Second Look



Before and After Images 2 week progression





Discussion

- The Second Look
- Ease of Follow Up
- The Data



American
Endovascular
& Amputation Prevention